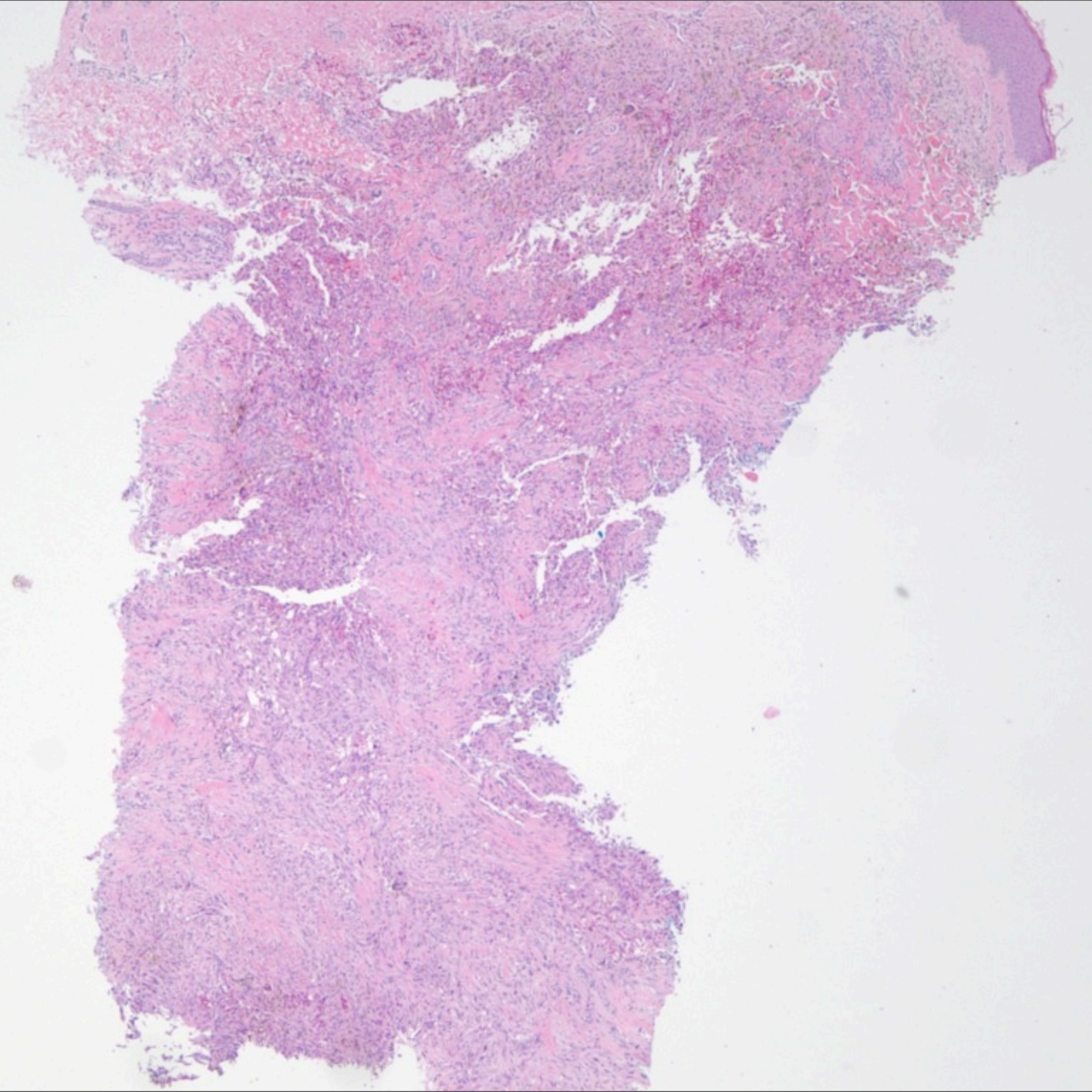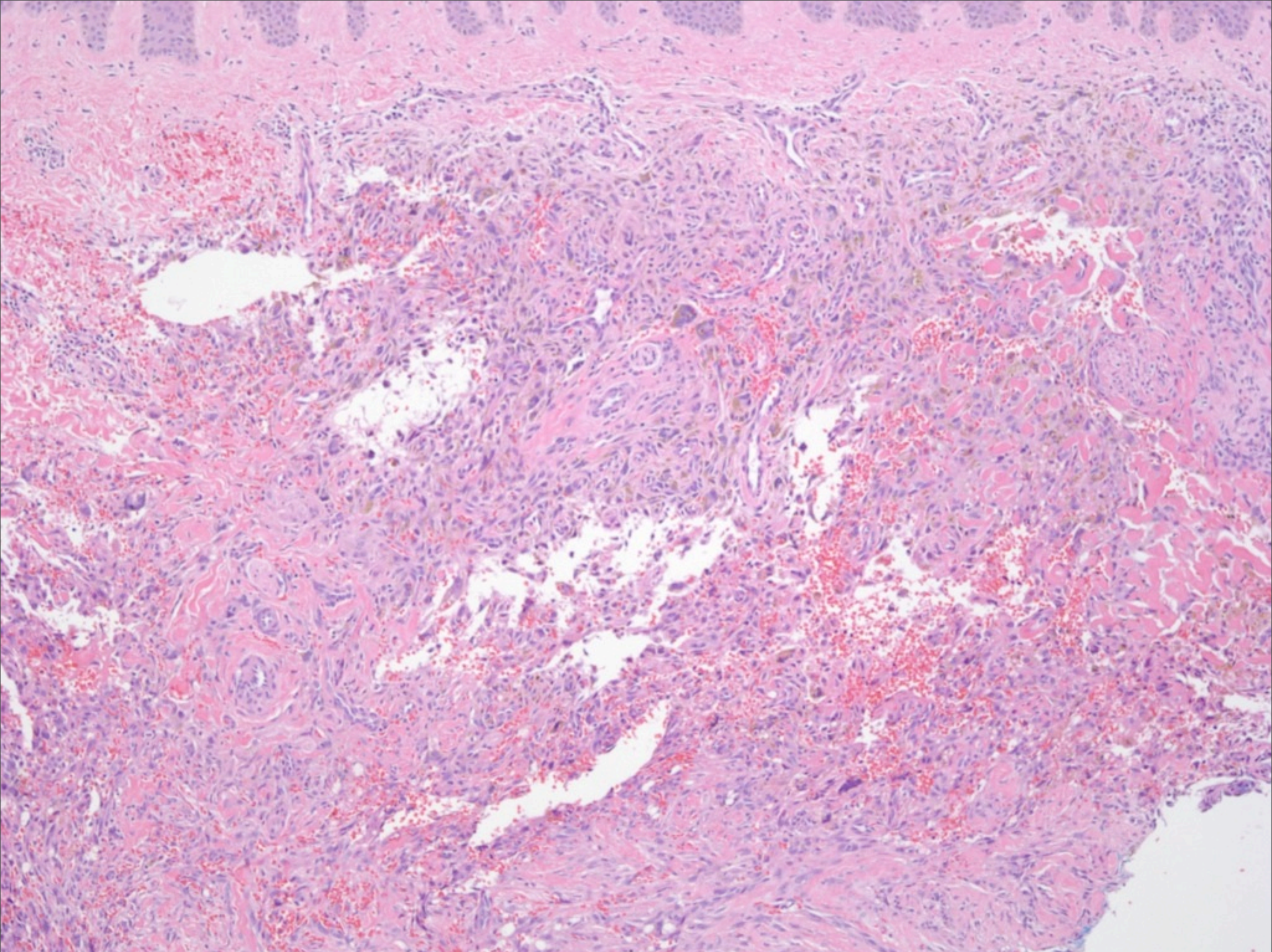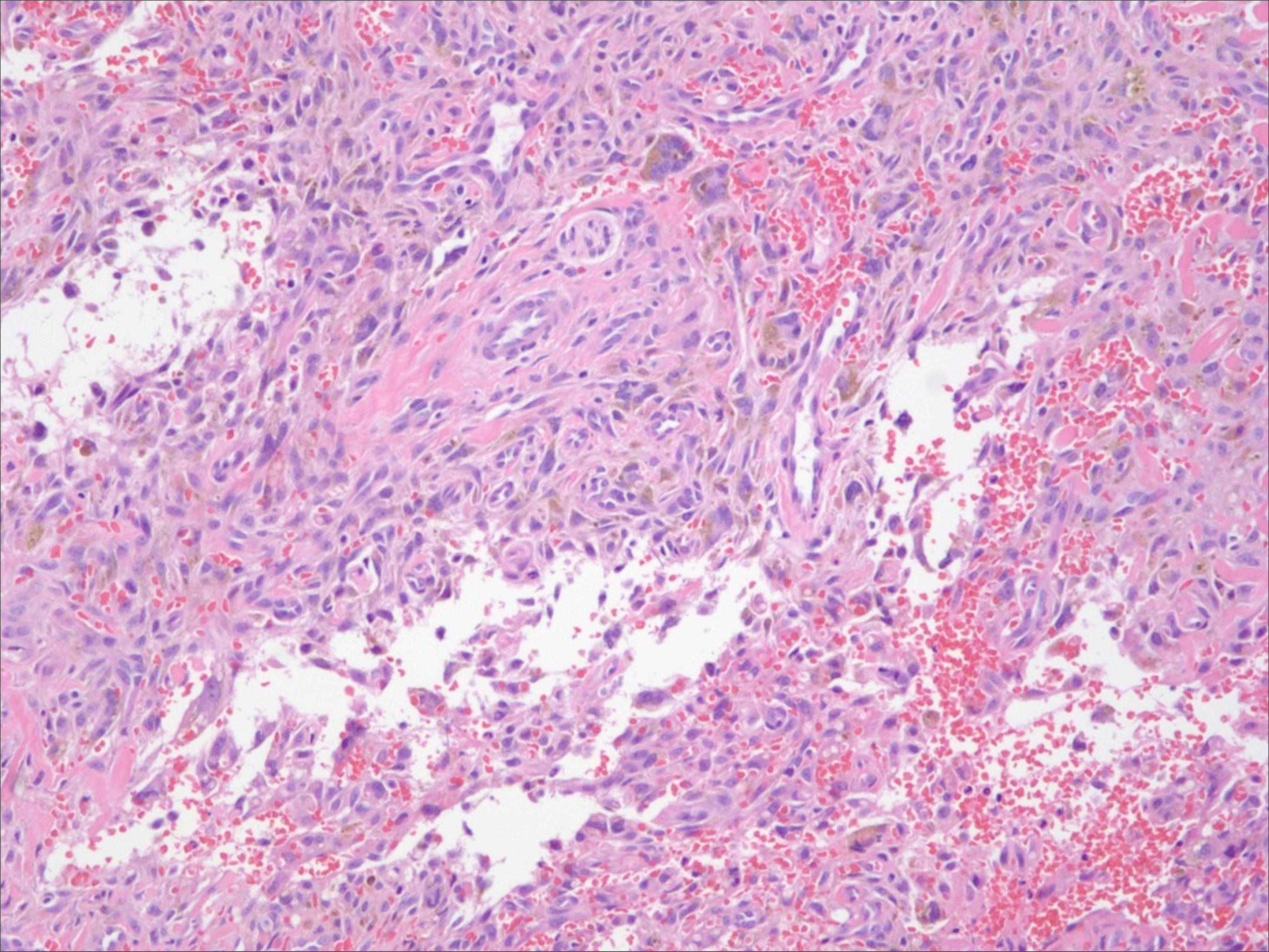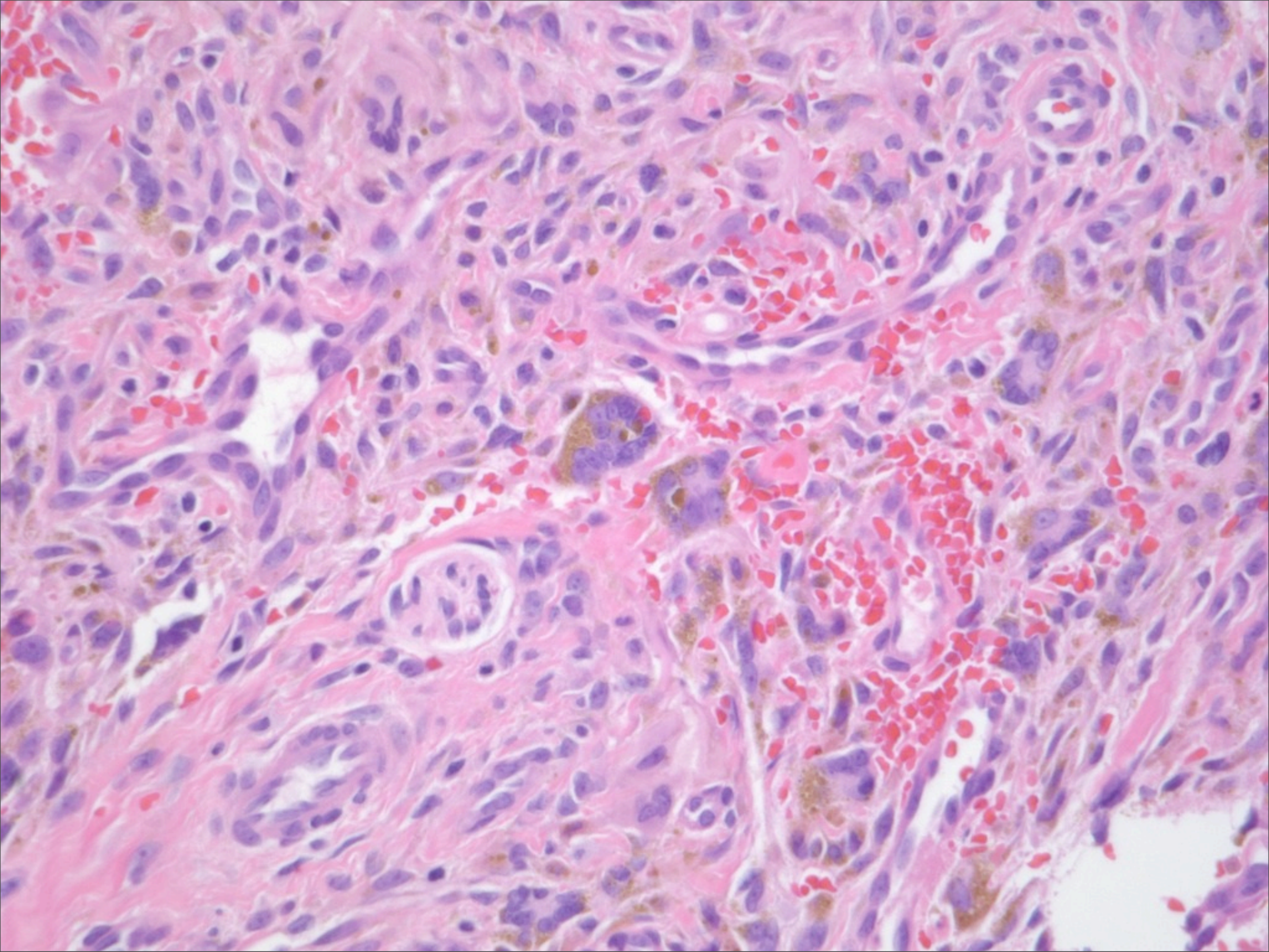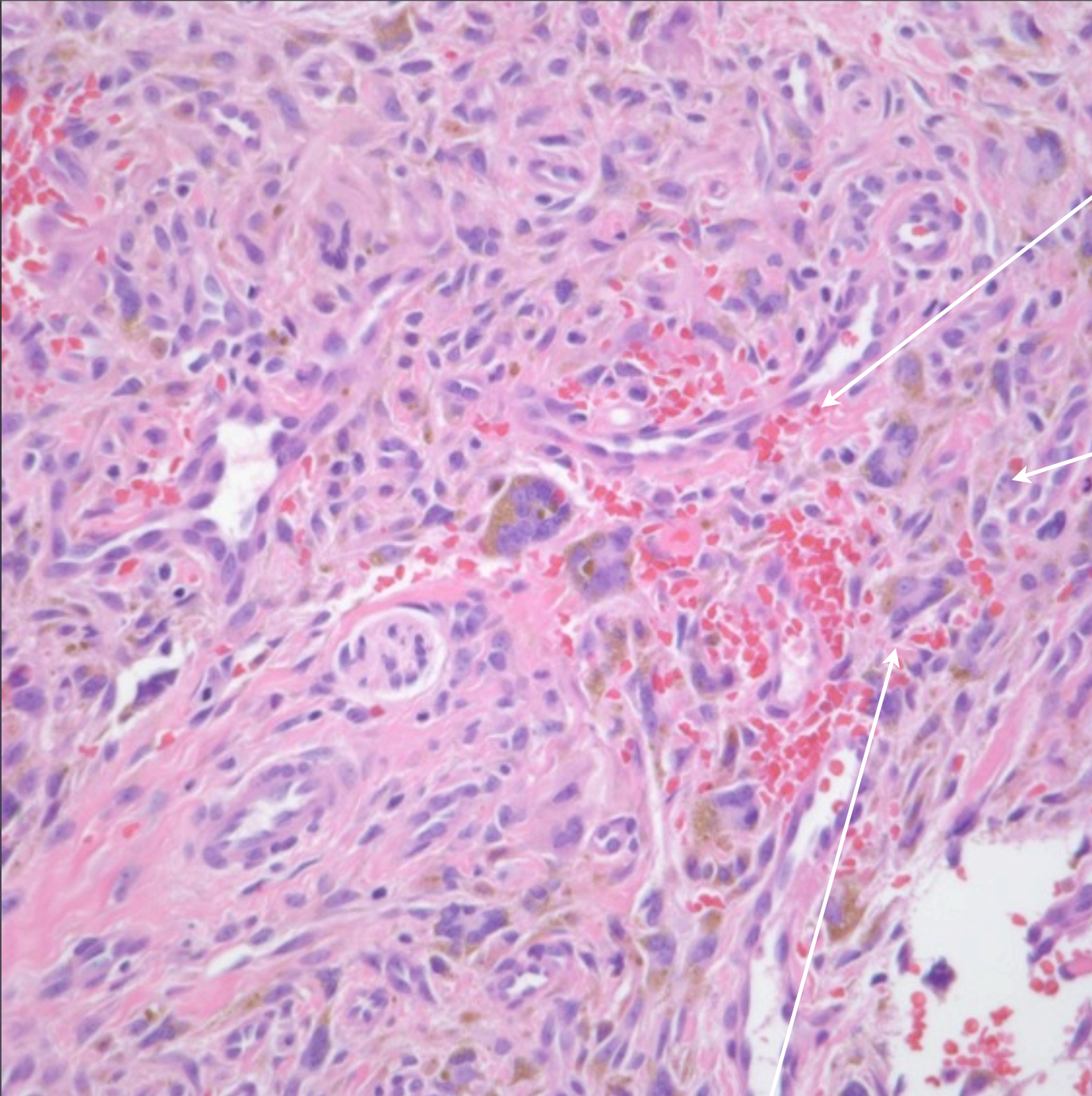


Dermatofibroma with Sclerosing Hemangioma Features



Hemorrhage and
hemosiderin macrophages

Spindle Cells
Entrapping Collagen

Spindle cells with Touton-type Giant Cells